

## SMARCB1 (INI-1)-DEFICIENT POORLY DIFFERENTIATED CARCINOMA OF SINONASAL TRACT

**Mudassar Hussain, Usman Hassan**

Department of Pathology, Shaukat Khanum Memorial Cancer Hospital and Research Centre, Lahore, Pakistan

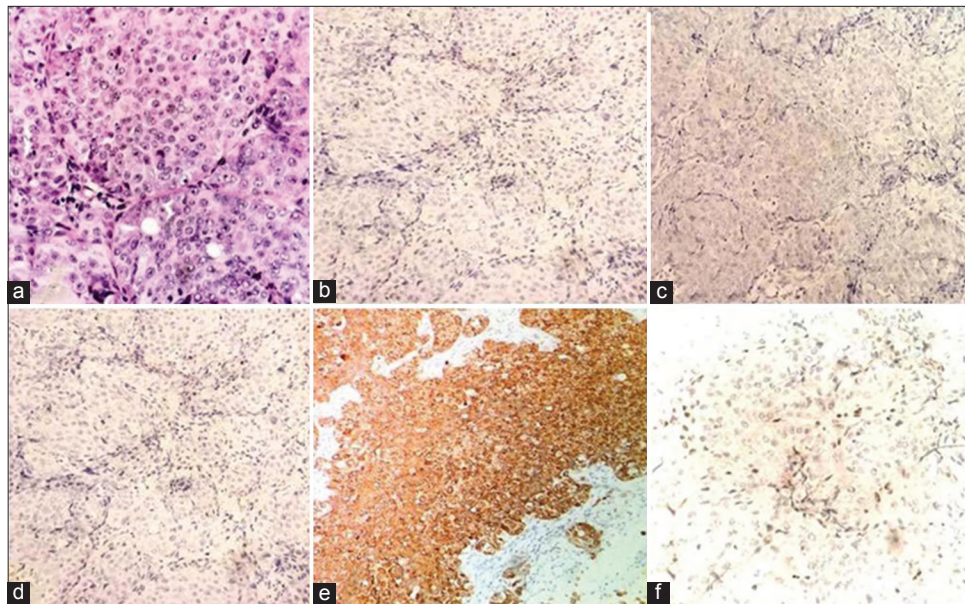
Received: 17 August 2016 / Accepted: 25 August 2016

A biopsy of a 40-year-old male was received with a history of mass in sinonasal region for the past 3 months. Tissue was composed of multiple fragments measuring 2 cm × 2 cm in aggregate. Histologically, the lesional cells were composed of nests of round-to-oval intermediate-sized epithelioid cells, surrounded by thin fibrovascular septae [Figure 1]. Tumor cells had indistinct cell membranes and showed moderate amount of amphophilic cytoplasm. The nuclei were round with clear chromatin and conspicuous nucleoli. No glandular or squamous differentiation was noted. Frequent mitotic activity was found.

Immunohistochemically, the tumor cells showed strong expression for cytokeratin (AE1/AE3) and negative

expression for p40, and nuclear protein in testis (NUT) immunostains. *In situ* hybridization for Epstein–Barr virus-encoded RNA was also negative. In addition, there was loss of INI-1 [Figure 1]. The final diagnosis was SMARCB1 (INI-1)-deficient poorly differentiated carcinoma of sinonasal tract.

The differential diagnoses of poorly differentiated carcinomas include basaloid squamous cell carcinoma, lymphoepithelial carcinoma, sinonasal undifferentiated carcinoma, small cell neuroendocrine carcinoma, poorly differentiated non-keratinizing squamous cell carcinoma and NUT midline carcinoma. Since the finding of loss of INI-1 in poorly differentiated carcinomas of sinonasal tract, a new entity has been approved by head and neck



**Figure 1:** (a) Poorly differentiated carcinoma showing round-to-oval cells with amphophilic moderate amount of cytoplasm and vesicular nuclei with prominent nucleoli, (b) p40 negative, (c) EBER negative, (d) nuclear protein in testis negative, (e) cytokeratin positive, (f) INI (SMARCB1) loss with positive internal control

**Correspondence:** Dr. Usman Hassan, Department of Pathology, Shaukat Khanum Memorial Cancer Hospital and Research Centre, Lahore, Pakistan. Email: usmanh@skm.org.pk

pathologists, i.e., SMARCB1 (INI-1)-deficient poorly differentiated carcinoma of sinonasal tract.<sup>[1]</sup>

SMARCB1 (INI-1), a tumor suppressor gene, is located on long arm of chromosome 22. SMARCB1 mutation has been observed in a large group of high-grade neoplasms exhibiting rhabdoid morphology.

There are very few cases of SMARCB1 (INI-1)-deficient sinonasal carcinomas reported in literature so far.<sup>[1,2]</sup> The majority of patients presented with symptoms including epistaxis, headaches, visual disturbances, nasal obstruction and facial pain.

Many INI-1-deficient sinonasal carcinomas were initially diagnosed as basaloid squamous cell carcinomas based on the presence of cohesive basaloid epithelial cells surrounded by palisading columnar cells.<sup>[3]</sup> Differentiating undifferentiated sinonasal carcinoma from SMARCB1 (INI1)-deficient sinonasal carcinoma can be tough as both share similar histological traits including large nuclei with prominent nucleoli, increased mitotic index, tumor necrosis and lack of squamous differentiation.<sup>[2]</sup>

The presence of rhabdoid cells is the most helpful feature that raises the possibility of SMARCB1 (INI-1)-deficient sinonasal carcinoma. Using SMARCB1, immunostain is a recommended way to recognize this rare entity and differentiate it from other poorly differentiated/undifferentiated sinonasal carcinomas.

Clinical outcomes and importance of INI-1 deficiency require long-term follow-up studies in days to come.

### Conflict of Interest

The authors declare that they have no conflict of interest.

### References

1. Agaimy A, Koch M, Lell M, *et al.* SMARCB1(INI1)-deficient sinonasal basaloid carcinoma: A novel member of the expanding family of SMARCB1-deficient neoplasms. *Am J Surg Pathol* 2014;38:1274-81.
2. Bishop JA, Antonescu CR, Westra WH. SMARCB1 (INI-1)-deficient carcinomas of the sinonasal tract. *Am J Surg Pathol* 2014;38:1282-9.
3. Turner JH, Reh DD. Incidence and survival in patients with sinonasal cancer: A historical analysis of population-based data. *Head Neck* 2012;34:877-85.